



UPPER EXTREMITY

Ulnar Nerve Transposition

AS DESCRIBED BY JOHN M. ITAMURA, M.D.
KERLAN-JOBE ORTHOPAEDIC CLINIC | LOS ANGELES, CA

TECHNOLOGY PLATFORM

CLARIX[®]CORD 1K Regenerative Matrix is cryopreserved human Amniotic Membrane and Umbilical Cord (hAMUC). AmnioX Medical’s proprietary CRYOTEK[®] preservation process retains the relevant natural structural and biological characteristics of the hAMUC tissue while devitalizing the living cells. CLARIX[®]CORD 1K Regenerative Matrix is used as a surgical covering, wrap or barrier.

CLINICAL HISTORY

56-year old, right-hand dominant male presented with right elbow pain. He has had mechanical symptoms as well as numbness, tingling, and loss of dexterity in his right hand. His range of motion was 13-115 degrees with full pronosupination. Patient had objective weakness of his intrinsic muscles, flexor capri ulnaris, and weakness from the flexor digitorum profundus to the small finger with a subluxating ulnar nerve.

PROCEDURE

An elbow arthroscopy was performed through the mid-lateral, posterior, medial and lateral portals, noting the presence of arthritis and loose bodies. Loose bodies were removed arthroscopically with the exception of a large anterior osteophyte, which was left for the open procedure. A medial incision was centered over the medial epicondyle and dissection was carried down to the ulnar nerve. A Medial Antebrachial Cutaneous (MABC) neurolysis was performed and the ulnar nerve was transposed (**FIG. 1**). A distal flap of the intramuscular septum was dissected and tagged to secure the nerve in the transposed position. The large anterior osteophyte was removed.

In this case, CLARIX[®]CORD 1K 4.0 x 3.0 cm was used as a soft-tissue barrier. The matrix was wrapped around the ulnar nerve and secured to itself proximally and distally with 2.0 monocril (**FIG. 2**). One can secure the transposition using CLARIX[®]CORD 1K (**FIG. 3**) and a flap of intramuscular septum, subcutaneous or submuscular. Skin was closed in the normal fashion and the patient was allowed motion as tolerated and started physical therapy 1 week post-operatively.

OUTCOME

Intraoperatively, the patient regained full motion. Three months after application of the CLARIX[®]CORD 1K matrix, the patient regained full extension and improved flexion compared to preoperative evaluation. In addition, the patient had return of full sensation, cessation of pain and improved strength in the ulnar nerve distribution.

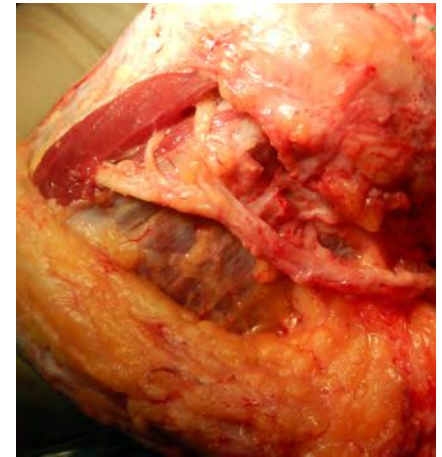

FIG. 1: TRANSPOSITION

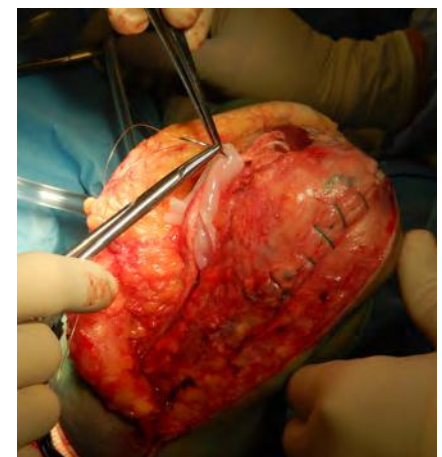


FIG. 2: APPLICATION

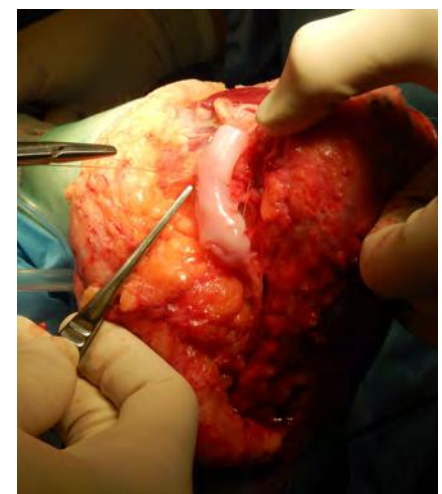

FIG. 3: OVERALL SECUREMENT